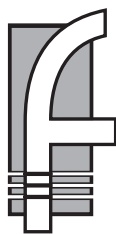

The
Metrolina Perio



PerioDontaLetter

PDLtm

Matthew D. Ficca, D.M.D., M.S.D., *Periodontics and Implant Dentistry*

Summer

From Our Office to Yours....

A key to implant success is the quantity and quality of the bone where the implant is to be placed.

The posterior area of the maxillary jaw has traditionally been one of the most difficult areas to successfully place dental implants. There is often insufficient quantity, quality and volume of available bone subjacent to the maxillary sinus.

Often when teeth are prematurely lost, pneumatization (expansion) of the sinus cavity occurs, which often obliterates a large amount of the remaining bone.

Sinus augmentation ("sinus lift") surgery is a method for elevating the sinus membrane from the sinus floor, creating a space that can be augmented with a variety of regenerative materials.

Several techniques can be used to augment the sinus and stimulate the formation of new bone. This issue of **The PerioDontaLetter** discusses the primary techniques currently in use.

As always, we welcome your comments and questions about these procedures.

Maxillary Sinus Augmentation

Sinus augmentation can greatly increase the chances for the successful placement of implants in the posterior maxillary region. Elevating the sinus membrane creates a space which is ideal to receive a variety of bone grafting materials. With sufficient time, sound bone of good quality can be developed to support the placement of dental implants, an excellent long-term solution to replace missing teeth.

Indications for Maxillary Sinus Augmentation

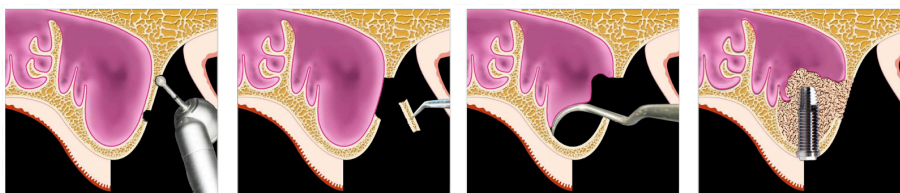
Sinus augmentation is necessary when the natural bone which existed at the floor of the sinus has been diminished or lost for a variety of reasons including: periodontal disease, atrophy with age, post tooth extraction of natural teeth, subsequent to significant surgery in the area for other reasons and anatomic variation.

Sinus augmentation may also be necessary because of continual pneumatization/enlargement of the sinus cavity with subsequent loss of the height of crestal bone. In this situation, as the sinus floor moves inferiorly, the volume of available bone is lost. The age of the patient and the loss of natural teeth are common contributing factors.

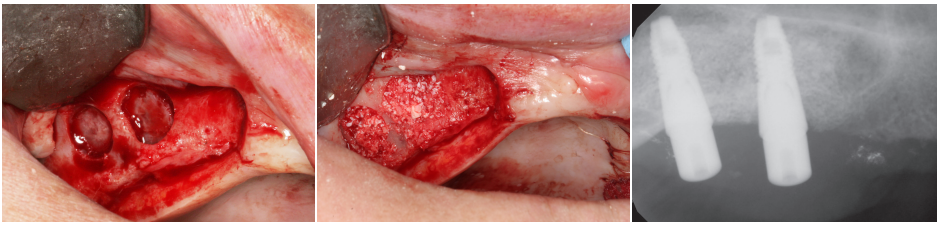
Sinus augmentation is recommended for patients presenting with insufficient quality and quantity of available bone to support a dental implant or implants.

Maxillary Sinus Augmentation Procedures

The two most frequently used sinus augmentation procedures are the lateral window approach, also known as the modified Caldwell-Luc Method, and the crestal or internal approach.



Figures 1, 2, 3 and 4. Schematics of the lateral window approach surgery with simultaneous implant placement.



Figures 5, 6 and 7. The crestal approach provided access to the sinus membrane for introduction of a bone graft into the sinus which allowed for delayed implant placement.

The lateral window approach requires creating a “window” into the sinus cavity. The sinus membrane is elevated to produce a negative space into which autografts, allografts, alloplasts, and xenografts may be placed. These materials can be used individually or in combination with other materials in a kind of bony cocktail. In addition, they may be combined with growth factors and other materials to jump-start bone formation.

The crestal approach generally relies on the presence of a greater amount of native bone, but is considerably less invasive. It is performed through the crest of the bone, up to, but not through, the membrane. The technique may require rotary drills, including Versah burs and piezoelectric surgical devices.

Bone graft material is introduced through the osteotomy, which serves to elevate the sinus membrane. If desired, the implant may be placed at the same time, tenting up the sinus membrane to allow the graft to mature into host bone encompassing the entire implant.

The crestal approach has less post operative issues than lateral sinus augmentation procedures. Success rates of greater than 93 percent are reported for the graft, or for implants placed in the grafted sinus.

The clinician has the choice to place an implant at the time of the crestal lift or after waiting for the bone to fully mature.

Cases of sinus grafts have been successfully carried out with simultaneous extraction and implant placement (also known as immediate implant placement), and with very small amounts of residual bone remaining – as little as 1-2mm.

Complications of Maxillary Sinus Augmentation

The most common surgical complication is perforation of the Schneiderian sinus membrane. This can occur in both the lateral window technique and the crestal approach. Sinus perforations increase the rates of postoperative sinusitis, infection, and graft failure, if the perforation is missed or not properly sealed.

During the delicate lifting phase or following surgery, inflammatory fluid in the sinus can easily infiltrate to the augmented site and compromise graft healing. This form of sinusitis is generally short term, and fortunately, infections do not frequently occur.

The other most often reported complication of the sinus lifting procedure is significant bleeding from the posterior superior alveolar artery, which can also

result in the loss of the graft or worse. While rare, the location and trajectory of this artery should be considered after Cone Beam Computed Tomography (CBCT) before every surgery. This complication can be considerably reduced or eliminated by the crestal surgical approach.

Maxillary septa are bone struts, traversing the sinus. They pose anatomical barriers which complicate elevating the sinus membrane without producing a tear.

CBCT evaluation of the sinus septa prior to a lateral antrostomy is suggested. Methods such as increasing the size of the bony window or preparing more than one lateral window can overcome the issue of bony septa.

Patient Selection

Patients with a history of sinusitis, allergies, or other sinus pathology may not be good candidates for maxillary sinus augmentation. These conditions may result in a thick membrane, which can complicate membrane elevation. When this or other preexisting sinus issues present, it is a good idea to consult with an ENT prior to initiating surgery. Patients must be well informed of the various sequelae of sinus surgery.

For many reasons smokers are particularly vulnerable to a plethora of sinus surgery complications, to say nothing of a much higher level of subsequent implant failures, making them very questionable candidates for either procedure.

Other contraindications to sinus augmentation for dental implants include uncontrolled diabetes, chemotherapy, previous unsuccessful sinus surgeries, neoplasm, radiotherapy, or prior LeFort I surgery.

Patient selection and education about the procedure is essential, as is the experience of the clinician performing the procedure, to minimize the risks of intra and post-operative complications.

Conclusion

Adequately performed sinus augmentation is a routine, very predictable, outpatient procedure and can often provide the requisite amount of bone to support an implant in occlusal function for a long time.



Figures 8, 9 and 10. Sinus augmentation by crestal approach, immediate implant placement surgery, and a 10-year follow up radiograph.

